

Posterior Approach to the Sciatic Nerve in Adults: Is Euclidean Geometry Still Necessary?

Carlo D. Franco, M.D.

Background: Every approach to the sciatic nerve in the buttocks currently requires the identification of pelvic bone structures. The large size of the nerve and its constant trajectory suggest that a simplified approach is possible.

Methods: During the first stage, 24 sciatic nerves in adult cadavers were dissected. The most significant findings were, (1) caudal to the piriformis muscle the sciatic nerve runs parallel to the midline (intergluteal sulcus); (2) the distance between the nerve and the intergluteal sulcus during this course is approximately 10 cm in adults, regardless of their gender, size, or body habits. In the clinical stage 20 blocks were performed at 10 cm from the midline of the buttocks using a nerve stimulator and insulated needles.

Results: All blocks were accomplished in less than 8.5 min. The technique proved easy to teach. Residents performed most of the blocks. Incision time, measured from the time of the injection, was less than 29 min in all cases. There were 18 successful blocks and 2 failures.

Conclusions: Because of the intimate relationship of the sciatic nerve to the bony pelvis, the position of this nerve in the buttocks is constant. Caudal to the piriformis muscle the nerve runs vertically between the ischium and the greater trochanter. The location of this narrow passage, not the buttocks' size, determines the position of the nerve. While the size of the buttocks is variable among different individuals and in the same individual at different stages of adult life, the relationship of the sciatic nerve to the pelvis is constant throughout life. Using this relationship to our advantage, a sciatic block in adults can be accomplished at 10 cm lateral to the intergluteal sulcus without a need for identification of buried structures or line tracings.

BLOCKING the largest peripheral nerve in the body can be accomplished at different levels and by different methods, although the posterior approach in the buttocks is one of the most common techniques. Labat¹ in 1922 described what is now considered to be the "classic" approach. It requires the identification of the posterior superior iliac spine (PSIS) and the highest point of the greater trochanter (GT). An "iliotrochanteric" line is then traced between these two structures and bisected. From this midpoint a perpendicular line is drawn downward and medially for 3 cm. Different authors have seen the need to prolong this perpendicular line up to 5 cm.^{2,3}

Winnie *et al.*⁴ in 1974 modified Labat's approach by adding a line from the sacral hiatus (SH) to the tip of the

GT. This modification eliminated the need to measure the perpendicular line, instead extending it until it intersects the new "sacrotrchanteric" line. Supposedly a perpendicular line of variable length would better reflect the position of the sciatic nerve according to patients' heights. This assumption may be erroneous. Because the perpendicular line runs down and medial, any prolongation of its length brings it closer to the midline, implying that the sciatic nerve of a taller patient would be located more medially than the nerve of a shorter patient. The notion that a taller person would necessarily have a taller sacrum and pelvis is refuted by the forensic literature.^{5,6} It is the length of long bones, especially femur and tibia, that determines the height of a person. Another problem with the classic techniques is the need to identify the PSIS, GT, and SH, which can sometimes be difficult.^{6,7,8}

Dissections show that the sciatic nerve has a very constant trajectory in the buttocks, confined to a narrow passage in the bony pelvis between the ischium and the greater trochanter. With these ideas in mind several dissections of the sciatic nerve in the buttocks were planned to gather data in an attempt to simplify the posterior approach to this nerve.

Materials and Methods

First Stage, Anatomy Laboratory

A total of 24 sciatic nerves in 12 adult cadavers were dissected. Some of the dissections were performed by medical students and some by the author himself. All cadavers were dissected on prone position with the lower extremities in adduction. The sciatic nerve and neighboring structures were identified. Position, trajectory, and different measurements were recorded. The information obtained was analyzed for repeated patterns and compared to the available literature.⁹⁻¹³ Originating from L4-5, S1-3 the sciatic nerve exits the pelvis through the greater sciatic foramen. At this point it rests on the ventral surface of the piriformis muscle describing a lateral and downward curve. At the inferior border of this muscle the nerve enters the buttocks covered superficially by the gluteus maximus muscle. From this point, and for the rest of its trajectory in the buttocks, the sciatic nerve became the target of our attention.

The analysis of our data as well as the review of the available literature shows that:

1. Caudal to the piriformis muscle, the sciatic nerve adopts a vertical trajectory that is parallel to the mid-

Chairman, Orthopedic Anesthesia, Cook County Hospital, and Assistant Professor of Anesthesiology, Rush Medical College, Chicago, Illinois.

Received from the Department of Anesthesiology and Pain Management, Cook County Hospital, Chicago, Illinois. Submitted for publication April 25, 2002. Accepted for publication November 8, 2002. Support was provided solely from institutional and/or departmental sources.

Address reprint requests to Dr. Franco: Department of Anesthesiology and Pain Management, Cook County Hospital, 1901 West Harrison Street, Chicago, Illinois 60612. Address electronic mail to: Carlofranco@aol.com. Individual article reprints may be purchased through the Journal Web site, www.anesthesiology.org.

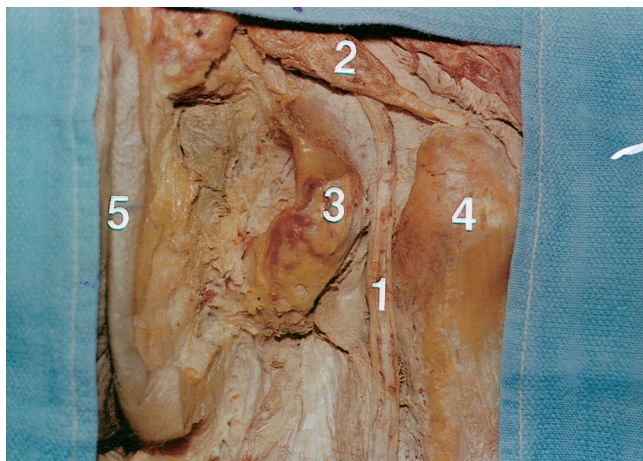

Fig. 1. The sciatic nerve (1) emerges in the buttocks caudal to the piriformis (2) and enters a narrow valley between ischium (3) and greater trochanter (4), running parallel to the intergluteal sulcus (5).

line. In surface anatomy the midline is represented by the intergluteal sulcus. The intergluteal sulcus, also known as natal cleft, is the result of the anchoring of the deep layers of the skin to the anococcygeal raphe and the dorsum of the coccyx up to the tip of the sacrum.

2. The point at which the sciatic nerve emerges in the buttocks caudal to the inferior border of the piriformis can be projected on a horizontal plane that passes through the uppermost aspect of the intergluteal sulcus. This is the same point at which the inferior gluteal vessels branch off.
3. Because the sciatic nerve's trajectory in the buttocks is parallel to the midline, the distance from it is constant. Such linear distance, as measured from the midline of the buttocks to the center of the nerve ranged from 9.7 cm to 10.3 cm in all 24 specimens (mean 10.1 cm \pm 0.2) with no specific tendency in either sex.
4. Soon after the sciatic nerve begins its parallel course to the midline of the buttocks, it enters a narrow valley carved between the ischium and the greater trochanter (fig. 1). A horizontal plane crossing this point projects in the surface roughly to the midpoint of the intergluteal sulcus.
5. The posterior femoral cutaneous nerve of the thigh emerges distal to the piriformis alongside the sciatic nerve and runs behind it until both nerves reach the thigh. Concerns about missing this branch if the block is performed low in the buttocks seem unfounded.
6. In as many as 12% of subjects^{9,13} the sciatic nerve exits the pelvis as two individual nerves, the posterior tibial and the common peroneal. However, because they share a common sheath that keeps them in intimate contact,^{9,12,13} this situation should not have clinical relevance.
7. Caudal to the piriformis, the gluteus maximus is the only muscle superficial to the sciatic nerve in the buttocks. The gluteus medius and minimus are proximal and lateral to it.

Male and Female Pelvises

The main difference between male and female bony pelvises is that the minor pelvis is relatively "roomier" in females.¹⁴ The female bones, on the other hand, are thinner than those of males.¹⁵ The net result is that the overall width of the pelvis is similar in both sexes, measuring, according to one source,¹⁴ 280 mm in males and 275 mm in females. In fact, the width of the pelvis according to a different source⁶ is similar in males and females at any given age, and variation in hip width reflects soft tissue, not bony, differences between the sexes.

Second Stage, Clinical Stage

Armed with this information the study progressed to the clinical stage. Institutional Review Board approval and written informed consents were obtained. All patients ASA I-III that came to the operating room (OR) for a surgical procedure below the knee without the need for a thigh tourniquet were eligible for the study. The blocks, as per our OR policy, were performed in the OR suite. An intravenous line was started and ASA standard monitors applied. Most of the patients were given 1 mg of midazolam plus 50 μ g of fentanyl in the OR; some patients received less. Based on associated pathology, body habits, and/or the patient's preference, the block was performed with the patient in either the prone position or in true lateral decubitus (both hips and knees flexed in a position similar to the one used to perform a neuroaxial block).

The blocks were performed with a 21-gauge, 10-cm, short-bevel insulated needle (Stimuplex, B. Braun, Bethlehem, PA) and a nerve stimulator (Stimuplex-DIG, B. Braun, Bethlehem, PA). Most of the blocks were performed by residents (CA-1 to CA-3) under the author's supervision. All residents had discussed the new technique with the author and were aware of its anatomic foundations. After estimating the midpoint of the intergluteal sulcus by simple inspection, a mark on the skin was placed 10 cm lateral to it in a straight line disregarding the buttocks curvature (fig. 2). Care was taken not to stretch the soft tissues during this measurement, because the subsequent recoil would translate into an underestimation of this distance. In a few cases performed on the lateral decubitus, we purposely stretched the redundant soft tissues of the nondependent buttock by taping the skin to the side of the bed (no recoil). This maneuver facilitated the measurement. When the operator was ready a handheld timer (Casio, Japan) was started and left running until incision time. The following times were recorded as actual readings:

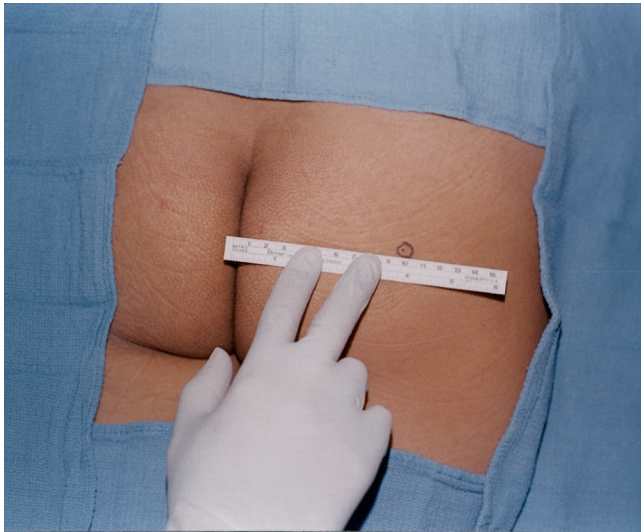


Fig. 2. A 10-cm measurement from the midline is done in a straight line from the midpoint of the intergluteal sulcus.

1. Time to skin mark on the buttocks (needle's entrance point). This time period includes the identification of the midpoint of the intergluteal sulcus and the 10-cm measurement lateral to it.
2. Time to first sciatic nerve response. Representing the time it takes to apply a disinfectant solution to the skin, raise a skin wheal, and give a subcutaneous injection of 2 to 3 ml of 1% lidocaine plain. Most importantly, it is the time it takes to bring the blocking needle in the vicinity of the sciatic nerve.
3. Time to injection. This time period starts with the first elicited response at 2 mA and finishes with a response still visible at 0.6 mA. It measures the time spent refining the position of the needle close enough to the nerve to elicit a response at low output.
4. Time to incision. This corresponds to the elapsed time between the start of injection and the incision and it is a reflection of onset and development of an adequate sensory block.
5. Total accumulated time. This is measured from the beginning of the procedure to incision, and reflects the overall efficiency of the technique.

The timer was left running continuously. The time periods were later calculated by subtracting the previous elapsed time from the actual reading. When the technique was performed prone the needle was advanced parallel to the midline (perpendicular to the table). When the technique was performed in the lateral position the needle was still advanced parallel to the midline (parallel to the table). Thus in either case the needle was advanced in reference to the midline (or the table or both) but independent of the buttocks' curvature (fig. 3). The technique was started with an output of 2.0 mA at 1 Hz (1 stimulation per second) and injected at 0.6 mA. If the needle failed to elicit a response, provided

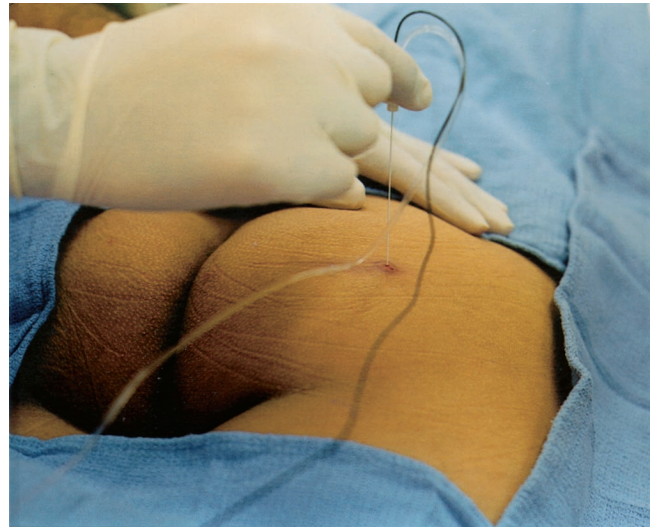


Fig. 3. The needle is advanced parallel to the midline or in reference to the table, disregarding the buttocks' curvature.

that the nerve stimulator was functional, a reposition was performed. As figure 4 shows, the nerve could only be located in a parasagittal plane slightly lateral or slightly medial to the needle's original position. It should be kept in mind that at a theoretical depth of 9 cm, a 10° correction in the insertion angle would move the tip of the needle approximately 1.6 cm away, and a 20° correction would move it approximately 3.4 cm away. All blocks were injected slowly and with frequent aspirations, using 30 ml of a solution of 1.5% mepivacaine plain plus 3 ml of 8.4% sodium bicarbonate. If no technical difficulties were encountered the patient was positioned for surgery and scrubbing was allowed to proceed. A saphenous nerve block, when indicated, was performed below the knee or in front of the medial malleolus using 3-5 ml of 1% mepivacaine plain.

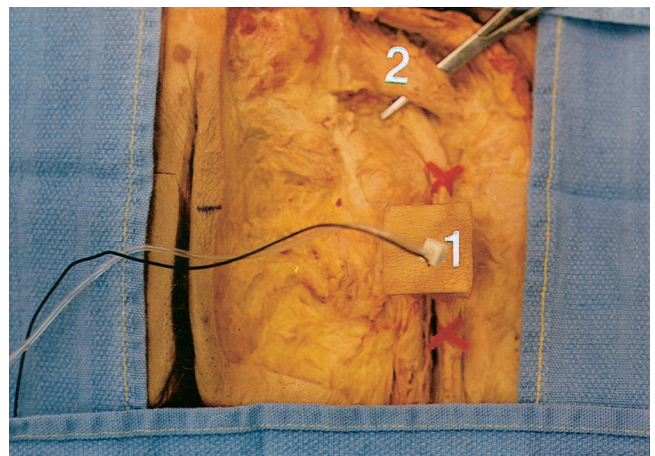


Fig. 4. Dissection performed around a 21-gauge insulated needle (I). A square patch of skin and underlying tissues were left intact. The sciatic nerve is shown with two red markers. Needle reposition, if necessary, has only two choices: slightly medial or slightly lateral. Piriformis muscle (2) is also shown.

Table 1. Population Demographics

	Mean \pm SD	Range
Age, yr	48.6 \pm 10.2	31–62
Height, cm	173.1 \pm 12.8	147–196
Weight, kg	86.6 \pm 13.6	68–125
Body mass index	28.3 \pm 3.9	21–35

The surgical procedures included below the knee amputations and different foot procedures such as bunions, hammertoe corrections, and others. At incision time the surgeon probed both the plantar and dorsal surfaces of the foot with a hemostatic clamp, followed by the incision.

The end of anesthesia was recorded as the time when the patient felt the subjective sensation of local anesthetic dissipation. If that happened after the patient had left the postanesthesia care unit, he or she was instructed to record the time of occurrence. The patient was visited or contacted by telephone 24 h later, and questioned about analgesia, side effects, residual anesthesia, and overall satisfaction.

Results

Eleven males and nine females were recruited for the study (table 1). Out of 20 blocks, 11 were performed with the patient in the prone position, and 9 were performed with the patient positioned laterally. Residents performed 15 blocks and the author performed the remaining 5. Table 2 shows that 40% of the blocks were accomplished at the first attempt, 85% needed three attempts or fewer, and all blocks were completed after six attempts or fewer. The height of patients who required only one attempt ranged from 147 cm (female) to 178 cm (male). The patients' weight in this subgroup ranged from 73 kg (female) to 100 kg (female). No pattern of reposition developed. Out of 20 blocks, 18 were successful and two failed.

Table 3 shows the different time periods recorded. All incisions were performed in less than 29 min from injection. Anesthesia dissipated 2–4 h after the injection in all patients, but a strong analgesia persisted in some patients up to 24 h later. During the 24-h evaluation all patients expressed satisfaction with the technique and reported no residual numbness, side effects, or complications. We could not reach one Hispanic male patient at the telephone number he provided as a contact, but his

Table 2. Number of Attempts

Attempts, n	Cases, n	%
1	8	40
≤ 3	9	45
> 3	3	15

Table 3. Time Periods

Time periods	Mean \pm SD	Range
Skin	0:23 \pm 0:11	0:11–0:52
First sciatic	2:12 \pm 1:09	1:04–4:50
Injection	1:13 \pm 0:44	0:11–2:43
Incision	20:57 \pm 3:25	14:07–28:45
Accumulated time	24:45 \pm 3:28	18:05–31:25

Time expressed in min:s.

block had worn off at discharge from the hospital and he had no complaints at the time.

Conclusions

Anatomy is the foundation on which the success of regional anesthesia rests. It contributes to the safety and consistency of a technique, but most importantly, it simplifies it. It does not seem reasonable that blocking a nerve averaging 2 cm in width,⁹ indeed the largest peripheral nerve in the body, would require the accurate palpation of pelvic bone structures that are sometimes hard to find. Several authors agree that determining the bony landmarks and/or performing a classic technique is usually complicated.^{6–8,16–19} Several attempts at simplification have been made. Rucci *et al.*, in 1989,¹⁹ proposed an approach in which the ischial tuberosity also needs to be identified. Chang *et al.*¹⁸ on the other hand, proposed in 1993 a rectal exam to find the ischial spine and indirectly the sciatic nerve. It is hard to believe that these modifications can qualify as “simplified” techniques, but perhaps they help to illustrate the need for a truly simplified approach.

The main goal of this study was to clinically prove what was learned in the anatomy laboratory. Therefore the stress was on feasibility and not necessarily on success rate. We chose for this study a volume of 30 ml of local anesthetic without epinephrine. The short duration of the anesthesia itself (2–4 h) may be related to this. Because the nerve is covered superficially by the gluteus maximus muscle, an argument could be made for the use of epinephrine, whenever not contraindicated, as the absorption from this site could potentially be significant.

While the population of this study is small, the technique was successfully used in adult patients of different gender, height, body habits, and ethnic backgrounds, including a 147-cm tall Hispanic woman and a 196-cm tall Caucasian male, all at approximately 10 cm. This seems to be proof of its versatility. The technique was also easy to teach; residents of all levels performed it successfully. In one case the skin mark was mistakenly placed at 8.5 cm from the midline (possibly because of stretching of the skin during measurement). This was in fact the only case where more than just a slight correction in the insertion angle was necessary.

It is not surprising that the time to place a mark on the skin was measured in seconds, as there are no buried landmarks to find. It is significant however, that the time to first sciatic response was less than 5 min in all cases, more so since this time also includes the infiltration of the skin. All incisions were performed in fewer than 29 min from the time of the injection. One of the reasons for this relatively short time to incision is that, having to perform the blocks in the OR, we allowed the scrubbing to proceed before ascertaining the quality of the sensory blockade. All patients were supine for surgery; the prone position would have required a longer waiting period. The mean accumulated time from the beginning of the procedure to incision was approximately 25 min (range 18–31 min) attesting to the efficiency and speed of the new technique.

One of the two blocks that failed was performed on an obese female (BMI 31) scheduled for a below the knee amputation. The 10-cm needle was found to be too short to reach her sciatic nerve (at the time we did not have a 15-cm insulated needle). After six attempts and with the needle hub pushed against the skin, an intermittent sciatic response was obtained, as the needle kept recoiling back. The surgeon probed the surgical site at about 16 min after the injection and the patient complained of pain. The other failed block occurred in a young female scheduled for removal of a bony mass over the lateral side of her foot. The block was performed at first attempt without any technical difficulties. More than 10 min after the incision was made she referred to an ill defined “discomfort” at the surgical site and requested to be asleep. At the end of a 55-min surgery the patient awoke pain free. Among the 18 patients that received a successful block nobody received more than 2 mg of midazolam and 100 μ g of fentanyl total for the entire case and many patients received less. Only the two patients with failed blocks received more sedation and/or propofol.

In this technique there are no bony landmarks to determine, and the needle is advanced in straight angles to the patient’s midline. This takes away the difficulty of determining what is “perpendicular to all planes” as needed with the classic and other approaches.^{1,3,7,20–22} A perpendicular to all planes approach in a round structure, such as the buttocks, means aiming the needle for the center of a sphere. There is a good chance of missing that center around a 360° radius.

The 10-cm distance from the intergluteal sulcus proposed here might well become 9.5 cm or 10.5 cm in different hands. Some others may even learn to use one measurement in some people and a slightly different one in others, and that is perfectly fine. The anatomic and clinical evidence suggest that the 10-cm mark can accommodate a large segment of the adult population, provided that the lower extremities are in adduction.

Because the nerve position in the bony pelvis is dictated by the location of the narrow passage between the

ischium and the greater trochanter, the actual size of the buttocks does not play a role. Thus, if a particular adult has a sciatic nerve located 10 cm from the midline when he weighs 70 kg, it should still be the case when his weight has reached 100 kg or more. What it does change is the relative position of the nerve in the buttocks. The adult with small buttocks has a nerve that seems “eccentric,” being much closer to the side than to the midline. In a “medium” sized patient the nerve seems to be very much centrally located, equidistant from the midline and the lateral side, while a large patient seems to have a nerve located closer to the midline. The fact that both male and female bony pelvises are similar in width⁶ makes these observations applicable to either sex.

The author has proposed to perform this block at the level of the midpoint of the intergluteal sulcus. This point is totally arbitrary but easy to visualize. Because the nerve in the buttocks runs parallel to the midline, the block can be attempted at different levels up and down the buttocks. Thus theoretically other techniques, such as supine⁸ and subgluteal,²³ could also benefit from this 10-cm measurement, avoiding the identification of bone structures. However, the block should not be attempted lateral to the top part of the intergluteal sulcus. The nerve at this point is describing a curve, so the distance to the midline is variable. Also, this is the area where the large inferior gluteal vessels are branching off. A block at this level could potentially carry a higher risk for intravascular injection.

During the performance of this technique with a nerve stimulator, a local twitch confined to the buttocks is obtained when the needle reaches the gluteus maximus muscle. As the needle penetrates the small amount of connective tissue that separates this muscle from the sciatic nerve there is a short period of “silence.” If this silence continues for more than a few centimeters beyond the gluteus maximus the operator should consider repositioning the needle. Any block performed in rational steps is usually described as a “technique.” The repositioning of the needle should be no different. Frequently a failure to elicit a response turns into an almost random search for a “lucky strike.” This new technique offers only two rational alternatives to repositioning, slightly lateral or slightly medial. If bone is contacted it usually indicates that the needle should be repositioned laterally, for the 10-cm measurement from the midline is more likely to fall short of the nerve, hitting the ischium, than being long enough to strike the greater trochanter at the outer side of the nerve.

Because the point of needle insertion falls close to the classic approach, the success rate with either technique should be similar, provided that the operator elicits similar endpoints (twitch or paresthesia). It is tempting to argue that because the new technique seems fast and easy to perform, more blocks could be accomplished

successfully in less time. However this remains to be determined.

This newly described technique is a rational effort to simplify both the posterior approach to the sciatic nerve in adults and the repositioning of the needle when that is necessary. It is grounded on anatomic facts and some common sense. The author understands that many practitioners may be reluctant to try a method advocating a "one size fits all" approach, instead of other methods that seem tailored to each particular patient. However, the pitfalls of the latter approaches have been outlined, while the simplicity and rationality of this new approach seem appealing. This new technique has nothing of the geometric beauty of the classic approaches. Instead, it is a technique based on averages and common occurrences. No doubt there will be patients to whom this does not apply; it remains to be seen how often that nonconformity will occur, and whether it will become relevant in clinical practice. The test of time should tell whether this attempt at simplification is instead an oversimplification.

The author thanks the Department of Anatomy, Rush Medical College, Chicago, IL, especially Thomas E. Durica, Ph.D. (Assistant Professor of Anatomy, Director of the Gross Anatomy Laboratory), and Robert J. Beck, Ph.D. (Anatomy Instructor), for their invaluable help. He also thanks Amir B. Rafizad, M.D. (Chief Anesthesiology Resident, Cook County Hospital, Chicago, IL) for his help in gathering the clinical data. The author dedicates this work to the memory of his father.

References

1. Labat G: Regional Anesthesia: Its Technique and Clinical application. Philadelphia, W.B. Saunders, 1922, pp 286-91
2. Gjessing J, Harley N: Sciatic and femoral nerve block with mepivacaine for surgery on the lower limb. *Anaesthesia* 1969; 24:213-8
3. Moore DC: Regional Anesthesia, 4th edition. Springfield, Charles C Thomas Publisher, 1981, pp 279-1
4. Winnie A, Ramamurthy S, Durrani Z, Radonjic R: Plexus blocks for lower extremity surgery. *ANESTHESIOLOGY Review* 1974; 1(6):11-6
5. Shipman P, Walker A, Bichell D: Human skeleton. Cambridge, Harvard University Press, 1985, pp 279-4
6. Hall J, Froster-Iskenius U, Allanton J: Handbook of normal physical measurements. Oxford, Oxford University Press, 1989, pp 254-08
7. Bridenbaugh P, Wedel D: The lower extremity: Somatic blockade, Neural Blockade in Clinical Anesthesia and Management of Pain, 3rd edition. Edited by Cousins MJ, Bridenbaugh PO. Philadelphia, Lippincott-Raven Publishers, 1998, pp 373-94
8. Raj P, Parks R, Watson T, Jenkins M: A new single-position supine approach to sciatic-femoral nerve block. *Anesth Analg* 1975; 54:489-4
9. Moore KL: Clinically Oriented Anatomy, 2nd edition. Philadelphia, Williams and Wilkins, 1984, pp 396-55
10. Grant JC: An Atlas of Anatomy, 6th edition. Baltimore, The Williams & Wilkins Company, 1972, pp 267-3
11. Snell RS: Clinical Anatomy for Medical Students, 3rd edition. Boston, Little, Brown and Company, 1986, pp 553-98
12. Gray H: Anatomy of the Human Body, 28th edition. Edited by Mayo C. Philadelphia, Lea & Febiger 1966, pp 1002
13. Bergman R, Thompson S, Afifi A, Saadeh F: Compendium of Human Anatomic Variation. Baltimore, Urban & Schwarzenberg, 1988, pp 497-8
14. Cunningham's Textbook of Anatomy, 5th edition. Edited by Robinson A. New York, William Wood and Company, 1928, pp 258
15. Hollinshead's Textbook of Anatomy, 5th edition. Edited by Rosse C, Gaddum-Rosse P. Philadelphia, Lippincott-Raven, 1997, pp 641-80
16. Rogers J, Ramamurthy S: Lower extremity blocks, Regional Anesthesia and Analgesia. Edited by Brown DL. Philadelphia, W.B. Saunders Company, 1996, pp 279-91
17. Wedel D, Brown D: Nerve blocks, Anesthesia, 3rd edition. Edited by Miller R. New York, Churchill Livingstone 1990, pp 1407-37
18. Chang P, Lang S, Yip R: Reevaluation of the sciatic nerve block. *Reg Anesth* 1993; 18:18-3
19. Rucci F, Trafficante F, Moresi M: A new approach to sciatic nerve block in the gluteal region. *Euro J Anaesth* 1989; 6:363-2
20. Mulroy M: Peripheral nerve blockade, Clinical Anesthesia, 3rd edition. Edited by Barash PG, Cullen BF, Stoelting RK. Philadelphia, Lippincott, Williams and Wilkins 1997; pp 669-97
21. Macrae W: Lower limb blocks, Principles and Practice of Regional Anesthesia, 2nd edition. Edited by Wildsmith JA, Armitage EN. Edinburgh, Churchill Livingstone, 1993, pp 189-02
22. Love W, Rathmell J, Tarver J: Regional anesthesia for acute pain management, Problems in Regional Anesthesia. Edited by Neal JM, Mulroy MF, Liu SS. 2000, 12:165-76
23. DiBenedetto P, Bertini L, Casati A, Borghi B, Albertin A, Fanelli G: A new posterior approach to the sciatic nerve block: A prospective randomized comparison with the classic posterior approach. *Anesth Analg* 2001; 93:1040-4